

Obstructive colon metastases from lobular breast cancer: report of a case and review of the literature

Massimiliano Mistrangelo¹, Paola Cassoni², Marinella Mistrangelo³,
Isabella Castellano², Elena Codognotto¹, Anna Sapino², Ginevra Lamanna⁴,
Francesca Cravero¹, Lavinia Bianco⁴, Gianluca Fora³, and Sergio Sandrucci⁴

¹Department of Digestive and Colorectal Surgery, Center of Minimally Invasive Surgery, University of Turin, Molinette Hospital, Turin; ²Department of Biomedical Sciences and Human Oncology, University of Turin, Molinette Hospital, Turin; ³Department of Oncology, Molinette Hospital, Turin; ⁴Department of Oncological Surgery, University of Turin, Molinette Hospital, Turin, Italy

ABSTRACT

Introduction. Gastrointestinal metastases from breast cancer are rare. One large series reported a rate of 0.7% of gastrointestinal metastatic manifestations from breast cancer, but its true incidence could be underestimated. Here we report a case of bowel obstruction caused by sigmoid metastases from breast cancer and describe its relevance to histological origin and clinical practice.

Methods. The clinical course and histopathology of the case are reviewed and compared with reports of similar cases in the literature.

Results. An 80-year-old woman presented with bowel obstruction. Her medical history included infiltrating lobular breast cancer treated with left radical mastectomy 25 years before the current presentation; 13 years later bone metastases developed and were treated with hormone therapy. In 2003 the patient came to our emergency department because of symptoms of bowel obstruction. A computed tomography (CT) scan revealed a mass in the distal sigmoid causing the obstruction. A colostomy was performed, followed by a second operation completed with Hartmann's procedure. Histological examination revealed metastases from invasive lobular carcinoma. The patient was discharged 45 days postoperatively and died 9 months later because of disease progression.

Conclusions. Although gastrointestinal metastases from breast cancer are rare, patients with diagnosed breast cancer, particularly invasive lobular carcinoma, should be regularly followed up with endoscopy, CT, endosonography and PET-CT when abdominal symptoms are present. This could permit early diagnosis of gastrointestinal metastases and improve treatment planning.

Introduction

Breast carcinoma, the most common cancer affecting women, accounts for approximately 32% of cancers in women and carries a lifetime risk of 1 in 10¹. In Italy, the estimated incidence is around 36,000 cases/year with 11,000 deaths per year², 10-20% of which are due to invasive lobular carcinoma (ILC), making it the breast cancer with the highest metastatic risk. Approximately 50% of patients with breast cancer will develop distant metastases during their lifetime, but the incidence of subclinical distant metastases is probably higher, as shown by autopsy series. Generally, metastases arise in the lung, bones, brain, liver and lymph nodes. Metastases to the gastrointestinal (GI) tract are rare. In a 1993 study, Borst *et al.*³ reported only 17 patients with GI metastases from breast cancer in a series of more than 2500 patients over an 18-year period. This reflects how rare these metastases are, i.e., less than 1%. Over a

Key words: breast cancer, invasive lobular carcinoma, metastases, gastrointestinal tract, bowel obstruction.

Authors' conflicts of interest: None.

Correspondence to: Massimiliano Mistrangelo, MD, PhD, Department of Digestive and Colorectal Surgery, Center of Minimally Invasive Surgery, University of Turin, Molinette Hospital, Corso A.M. Dogliotti 14, 10126 Turin, Italy.
Tel +39-347-3783799;
+39-011-6601632;
fax +39-011-6336725;
e-mail mistrangelo@katamail.com;
mmistrangelo3@molinette.piemonte.it

Received June 15, 2010;
accepted October 21, 2010.

30-year period, however, more than 1000 cases of GI metastases from breast cancer were reported in another study from 1993⁴. The incidence of metastases to the GI tract at autopsy is between 6% and 35%^{5,6}. The stomach and small intestine are more frequent metastatic GI sites than either the colon or rectum. Extrahepatic GI metastases from lobular breast cancer occur in 6-18% of cases; the stomach is the most frequent and the rectum the least frequent metastatic site³. Synchronous GI intestinal metastases from breast cancer are occasionally reported⁷; however, there is no evidence in the literature that could guide treatment. Generally, GI metastases occur 4 to 5 years after a diagnosis of primary breast cancer. Coexisting metastases in other tissue are present in up to 90% of cases.

The prognosis of breast cancer depends on tumor size, histological subtype, hormone receptors and invasion of axillary lymph nodes. The median survival after a diagnosis of GI metastases is about 1 year⁸.

Here we report a case of intestinal occlusion caused by sigmoid metastases from lobular breast cancer. This case highlights the relevance of GI metastases from breast cancer as a cause of abdominal symptoms, which could end in bowel obstruction.

Case report

In January 2003, a 79-year-old woman complaining of abdominal pain and progressively worsening constipation underwent surgical examination including rigid proctoscopy. The examination was negative for rectal lesions but revealed a pelvic mass compressing the rectal wall. Subsequent computed tomography (CT) revealed an obstructive lesion in the distal sigmoid with suspected infiltration of the uterus and bladder. The CT scan also showed bowel obstruction requiring an emergency operation.

The patient's medical history included left-sided radical mastectomy for ILC performed in 1978 at the age of 55 years. The estrogen and progesterone receptors status and histological tumor grade were unknown. In 1991 she presented with bone metastases treated with hormone therapy (tamoxifen). In January 2001 bone metastases had progressed to involve the ribs bilaterally. Scintigraphy performed several months later showed metastases to the skull, breast bone, scapula, vertebrae, pelvis, left forearm and femurs. Conservative treatment was initiated.

Notably, her early history had included a complaint of abdominal pain and progressive constipation with bowel obstruction. Based on the symptoms and examination findings, the patient underwent exploratory laparotomy which confirmed the presence of a bulky pelvic mass involving the sigmoid colon. No signs of carcinosis or other secondaries (liver, spleen, bowel) were found. Left diversion colostomy was performed to resolve the occlusion.

Nine days after the operation, fecal peritonitis with sepsis developed due to stomal retraction and necrosis; a new laparotomy was performed with a Hartmann procedure because of cleavage between the uterus and bladder. Postoperative respiratory insufficiency and surgical site infection caused by *Enterobacter cloacae* were treated conservatively. Postoperative hemorrhage was treated with blood transfusions. The patient was discharged 45 days after surgery.

Definitive histological examination disclosed invasion of the descending and sigmoid colon by metastases from ILC. All resected lymph nodes were found to be metastatic (14/14); omental metastases were also found. The patient died 9 months after surgery because of disease progression.

Pathology

The final histological examination revealed sigmoid metastases from lobular breast cancer. The predominant histological subtype of GI metastases from a primary breast cancer is ILC. The most common type of GI involvement is diffuse intramural infiltration mimicking linitis plastica of the stomach; histological examination shows massive neoplastic infiltration of noncohesive malignant cells with signet ring morphology, individually dispersed or arranged in a single-file linear pattern. In our patient, the infiltration was more prominent in the subserosal tissue and the longitudinal muscle wall of the descending and sigmoid colon (Figure 1). Four extensively metastatic lymph nodes were present in the perivisceral tissue, where diffuse vascular invasion was also noted (Figure 2).

Discussion

Breast carcinoma is the most frequent cancer in women and a significant cause of morbidity and mortality. Some 30-80% of patients will develop metastatic disease following therapy. Jain *et al.*⁹ examined 1238 patients with operable breast cancer and identified the sites of metastatic disease. They found that infiltrating ductal carcinoma (IDC) recurred more commonly in lung ($P < 0.05$), pleura ($P < 0.05$) and bone ($P < 0.05$), while ILC metastasized more to the bone marrow ($P < 0.01$) and peritoneum ($P < 0.01$). Bone involvement as the initial presentation of distant metastatic disease occurred in over 50% of the women with ILC, significantly more often than in those with IDC (34%; $P < 0.01$). Survival was similar for the 2 groups.

GI metastatic tumors are a rare entity. GI manifestations of metastatic breast cancer may occur many years after the primary breast cancer diagnosis, usually between 5 and 20 years but even up to 30 years in some cases¹⁰. As suggested by Borst *et al.*³ ILC, although less common than IDC, is more likely to metastasize to the

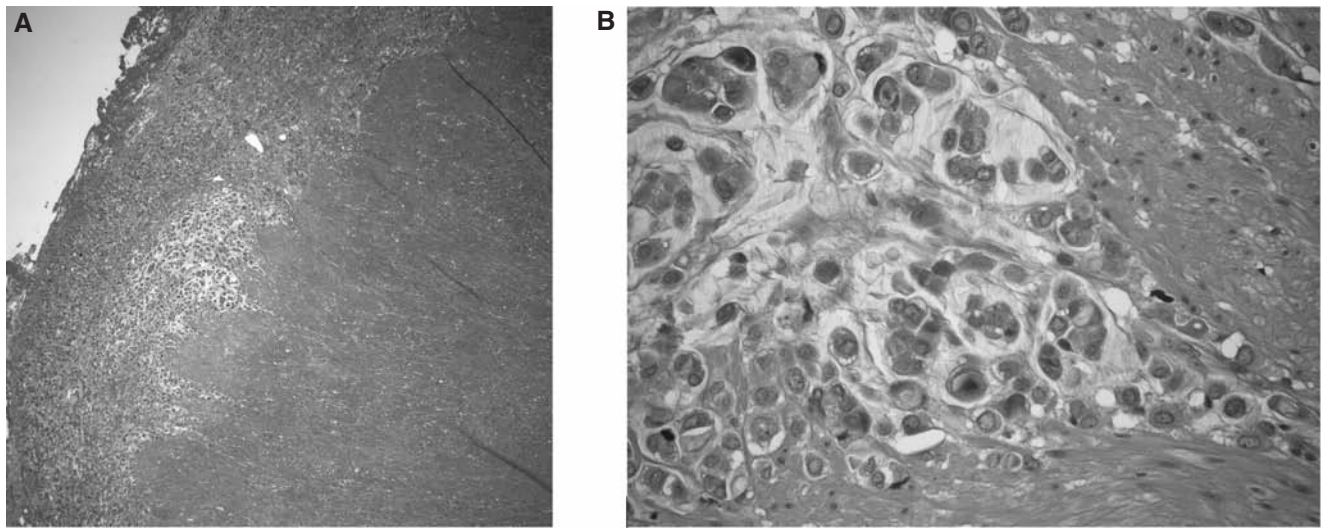


Figure 1 - A) Massive neoplastic infiltration of the malignancy into the sub-serosal tissue and the longitudinal muscle wall of the descending and sigmoid colon tract (hematoxylin and eosin, 4x). B) Neoplastic cells with a non-cohesive signet ring appearance (hematoxylin and eosin, 40x).

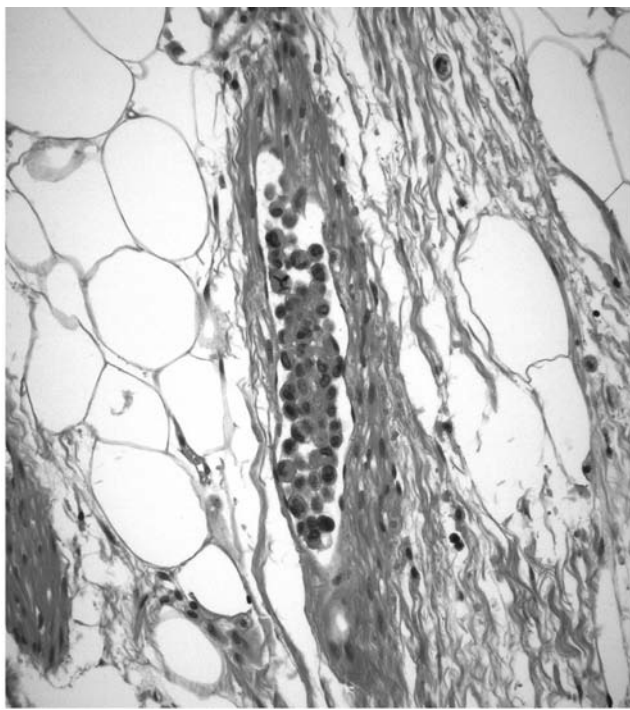


Figure 2 - Diffuse vascular invasion into the perivisceral fatty tissue (hematoxylin and eosin, 10x).

GI tract: 4.5% in ILC *versus* 0.2% in IDC. GI metastases are usually associated with extensive spread. Winston *et al.*¹¹ suggested that loss of expression of the cell-cell adhesion molecule E-cadherin in ILC may contribute to the differences in metastatic patterns when compared to IDC.

The localization of GI metastases from breast cancer varies. Fink *et al.*¹² reported localization at the tip of the tongue; oropharyngeal and esophageal sites have been

sporadically reported¹³. Metastatic involvement of the stomach is the most frequent (up to 15%), as shown by autopsy series¹⁴⁻¹⁷. Breast cancer is one of the major causes of gastric metastases. Metastatic involvement of the small bowel is recognized at autopsy, but clinical presentation is uncommon. The terminal ileum is more often involved than the rest of the small bowel^{18,19}. Metastasis to the duodenum^{20,21} and the appendix²² has sometimes been reported.

Colon metastases are found in up to 12% of autopsies^{23,24}. Graham²⁴ reported colonic involvement in only 4% of patients (12 of 300), similar to Klein²⁵ (3%; 20 of 720 cases). Generally, breast cancer metastasis to the colon is hematogenous, although it may also result from dissemination of tumor cells by peritoneal and lymphatic routes. Metastasis to the colon²⁶⁻²⁸ is less rare than to either the rectum^{7,29-31} or the anus^{32,33}. Taal *et al.*⁸ reported 17 cases of colorectal metastases from breast cancer over a 15-year period. Few reports describe rectal metastases from breast cancer; in the majority of cases, the metastatic manifestations are diagnosed as tumor recurrence. Yanagisawa *et al.*⁷ were the first to describe synchronous rectal metastases. Hepatobiliary tract involvement has been occasionally described^{34,35}. Other metastatic manifestations are ascites secondary to peritoneal carcinomatosis and secondary tumors in the diaphragm, genitourinary tract, retroperitoneum, mesenteric lymph nodes, abdominal wall and subcutaneous tissues.

Symptoms vary depending on the localization of the disease. Clinical symptoms have been described in less than 1% of cases³⁶. Metastasis to the colon may be asymptomatic or present as an abdominal mass and multiple strictures. As in our case, progressive constipation may result, leading to complete bowel obstruction requiring emergency surgery. Recognition of the range

of possible presentations is important for early and accurate diagnosis and treatment. As suggested by Nazareno *et al.*¹⁹, GI tract involvement must be considered in any woman with a previous history of breast malignancy presenting with new GI complaints.

Diagnosis is challenging because the symptoms include those of primary GI tumors, Crohn's disease and several other benign tumor processes. Endoscopy, gastroscopy and colonoscopy are often unable to detect a mass in the lumen. When the mechanism of obstruction is extrinsic, the mucosa will be normal¹⁹. Thus, biopsy could be negative since the metastases often appear in the muscularis propria, without endothelial changes, and can mimic linitis plastica. CT is the imaging method of choice³⁷ because it will usually reveal an abdominal mass. A deep biopsy or laparotomy might be necessary for diagnosis. Recently, ¹⁸F-fluorodeoxyglucose (FDG) positron emission tomography (PET) has proven useful in these patients. Laoutliev *et al.*³⁸ suggest that ¹⁸F-FDG-PET be considered when available as an early diagnostic supplement in patients with a history of breast cancer.

There is no evidence to guide the management of these patients. Surgical treatment, often palliative, should be reserved for patients with isolated lesions, emergencies (perforation, obstruction and hemorrhage), and cases where tumor debulking could improve the effect of chemotherapy. Some authors reported long-term survival after radical surgery when a single metastasis was found. If, in addition to GI metastases, metastases to other sites are present and/or the patient's condition is unfavorable, other treatment modalities (hormones, chemo- and radiotherapy) may be indicated depending on prior therapy. The overall response rate to non-surgical treatment in breast cancer patients with gastric metastases is 32% and 53% in those with colorectal metastases⁸.

In cases of synchronous metastases, some authors suggest taking an initial approach with chemotherapy and hormone therapy⁷. Systemic treatment with anti-cancer drugs and hormonal agents is recommended as first-line treatment in this patient subgroup. These therapies can be extremely effective and may help to avoid unnecessary surgery⁷.

The main causes of death among patients with known GI metastases are GI obstruction, perforation, septic shock and total renal failure. As suggested by Signorelli *et al.*²⁷, a better knowledge of GI metastases from primary breast carcinoma is warranted because appropriate management may result in longer survival.

Conclusions

Colorectal breast carcinoma metastases are very rare. ILC metastasizes significantly more often than IDC to the GI tract. This an important aspect in the follow-up of

these patients, especially when they present with abdominal complaints. Physicians should be aware of these unusual metastatic patterns of breast cancer in order to improve treatment and prognosis.

References

1. Rubin P: Clinical oncology, 7th ed, pp 187-211, WB Saunders Co, Philadelphia, 1993.
2. AIRTUM Working group: I tumori in Italia – Documento annuale 2009. I nuovi dati di incidenza e mortalità, periodo 2003-2005, available at <http://www.registri-tumori.it/cms>.
3. Borst MJ, Ingold JA: Metastatic patterns of invasive lobular versus invasive ductal carcinoma of the breast. *Surgery*, 114: 637-641, 1993.
4. Madeya S, Borsch G: Gastrointestinal metastases of breast carcinoma. *Gastrointest Endoscopy*, 39: 103-104, 1993.
5. McLemore EC, Pockaj BA, Reynolds C, Gray RJ, Hernandez JL, Grant CS, Donohue JH: Breast cancer: presentation and intervention in women with gastrointestinal metastases and carcinomatosis. *Ann Surg Oncol*, 12: 886-894, 2005.
6. Washington K, McDonagh D: Secondary tumours of the gastrointestinal tract: surgical pathologic findings and comparison with autopsy survey. *Mod Pathol*, 8: 427-433, 1995.
7. Yanagisawa K, Yamamoto M, Ueno E, Ohkouchi N: Synchronous rectal metastasis from invasive lobular carcinoma of the breast. *J Gastroenterol Hepatol*, 22: 601-602, 2007.
8. Taal BG, den Hartog Jager FCA, Steinmetz R, Peterse H: The spectrum of gastrointestinal metastases of breast carcinoma II. The colon and rectum. *Gastrointest Endoscopy*, 38: 136-141, 1992.
9. Jain S, Fisher C, Smith P, Millis RR, Rubens RD: Patterns of metastatic breast cancer in relation to histological type. *Eur J Cancer*, 29A: 2155-2157, 1993.
10. Benfiguig A, Anciaux ML, Eugene CI, Benkemoun G, Etienne JC: Gastric metastases of breast cancer occurring after a cancer free interval of 30 years. *Ann Gastroenterol Hepatol*, 28: 175-177, 1992.
11. Winston CB, Hadar O, Teicher JB, Caravelli JE, Sklarin NT, Panicek DM, Liberman L: Metastatic lobular carcinoma of the breast: patterns of spread in the chest, abdomen and pelvis on CT. *Am J Roentgenol*, 175: 795-800, 2000.
12. Fink I, Garb J: Carcinoma of the tip of the tongue: a case of metastasis from a malignant tumor of the breast. *Am J Surg*, 62: 138-141, 1943.
13. Varanasi RV, Saltzman JR, Krims P, Crimaldi A, Colby J: Breast carcinoma metastatic to the esophagus: clinicopathological and management features of four cases, and literature review. *Am J Gastroenterol*, 90: 1495-1499, 1995.
14. Chang SE, Burrell MI, Brand MH, Garsten JJ: The protean gastrointestinal manifestations of metastatic breast carcinoma. *Radiology*, 126: 611-617, 1978.
15. Joffe N: Metastatic involvement of the stomach secondary to breast carcinoma. *Am J Roentgenol Radium Ther Nucl Med*, 123: 512-521, 1975.
16. Reiman T, Butts CA: Upper gastrointestinal bleeding as a metastatic manifestation of breast cancer: a case report and a review of the literature. *Can J Gastroenterol*, 15: 67-71, 2001.
17. Van Trappen Ph, Serreyn R, Elewaut AE, Cocquyt V, Van Belle S: Abdominal pain with anorexia in patients with breast carcinoma. *Ann Oncol*, 9: 1243-1245, 1998.
18. Hansen RM, Lewis JD, Janjan NA, Komorowski RA: Occult carcinoma of the breast masquerading as primary adenocarcinoma of the small intestine. A case report. *J Clin Gastroenterol*, 10: 213-217, 1988.

19. Nazareno J, Taves D, Preiksaitis HG: Metastatic breast cancer to the gastrointestinal tract: a case series and review of the literature. *World J Gastroenterol*, 12: 6219-6224, 2006.
20. Hartmann WH, Sherlock P: Gastroduodenal metastases from carcinoma of the breast. An adrenal steroid-induced phenomenon. *Cancer*, 14: 426-431, 1961.
21. Nihon-Yanagi Y, Park Y, Ooshiro M, Aoki H, Suzuki Y, Hiruta N, Kameda N, Katoh R: A case of recurrent invasive lobular carcinoma of the breast found as metastasis to the duodenum. *Breast Cancer*, 16: 83-87, 2009.
22. Burney RE, Koss N, Goldenberg IS: Acute appendicitis secondary to metastatic carcinoma of the breast. A report and review of two cases. *Arch Surg*, 108: 872-875, 1974.
23. Cifuentes N, Pickren JW: Metastases from carcinoma of mammary gland: an autopsy study. *J Surg Oncol*, 11: 193-205, 1979.
24. Graham WP, Goldman L: Gastrointestinal metastases from carcinoma of the breast. *Am Surg*, 159: 477-480, 1964.
25. Klein MS, Sherlock P: Gastric and colonic metastases from breast cancer. *Am J Dig Dis*, 17: 881-886, 1972.
26. Théraux J, Bretagnol F, Guedj N, Cazals-Hatem D, Panis Y: Colorectal breast carcinoma metastasis diagnosed as an obstructive colonic primary tumor. A case report and review of the literature. *Gastroenterol Clin Biol*, 33: 1114-1117, 2009.
27. Signorelli C, Pomponi-Formiconi D, Nelli F, Pollera CF: Single colon metastasis from breast cancer. A clinical case report. *Tumori*, 91: 424-427, 2005.
28. Uygum K, Kocak Z, Altaner S, Cicin I, Tokatli F, Uzal C: Colonic metastasis from carcinoma of the breast that mimics a primary intestinal cancer. *Yonsei Med J*, 47: 578-582, 2006.
29. Cano-Maldonado AJ, Diaz-Tie M, Vives-Rodríguez E, Lux KM, Basanta-Calderón Y, Alcázar-Montero JA, Durana-Tonder C, Adrio-Díaz G: Rectal metastasis of lobular breast carcinoma. *Rev Esp Enferm Dig*, 100: 438-445, 2008.
30. Cervi G, Vettoretto N, Vinco A, Cervi E, Villanacci V, Grigoletto P, Giulini SM: Rectal localization of metastatic lobular breast cancer: report of a case. *Dis Colon Rectum*, 44: 453-455, 2001.
31. Bamias A, Baltayiannis G, Kamina S, Fatouros M, Lymperopoulos E, Agnanti N, Tsianos E, Pavlidis N: Rectal metastases from lobular carcinoma of the breast: report of a case and literature review. *Ann Oncol*, 12: 715-718, 2001.
32. Balibrea JM, Cantero R, García-Calvo M, García-Pérez JC, Furió-Bacete V, Blanco J, Balibrea JL: Perianal metastasis from lobular breast carcinoma. *Clin Transl Oncol*, 9: 606-609, 2007.
33. Haberstick R, Tuech JJ, Wilt M, Rodie JF: Anal localization as first manifestation of metastatic ductal breast carcinoma. *Tech Coloproctol*, 9: 237-238, 2005.
34. Schwarz RE, Klimstra DS, Turnbull AD: Metastatic breast cancer masquerading as a gastrointestinal primary. *Am J Gastroenterol*, 93: 111-114, 1998.
35. Franco D, Martin B, Smadja C, Szekely AM, Rougier P: Biliary metastases of breast carcinoma. The case for resection. *Cancer*, 60: 96-99, 1987.
36. Hoff J, Portet R, Becue J, Fourtainer G, Bugat R: Métastases digestives des cancers du sein. *Ann Chir*, 37: 281-284, 1983.
37. Kidney DD, Cohen AJ, Butler J: Abdominal metastases of infiltrating lobular breast carcinoma: CT and fluoroscopic imaging findings. *Abdom Imaging*, 22: 156-159, 1997.
38. Laoutiev B, Harling H, Neergaard K, Simonsen L: Rectal metastasis from infiltrating lobular breast carcinoma: imaging with 18F-FDG PET. *Eur Radiol*, 15: 186-188, 2005.